Avian Radiography

Kenneth R. Welle DVM
Diplomate ABVP, Avian Practice
All Creatures Animal Hospital
2001 N. Linview
Urbana, IL 61801

Birds are very well suited to radiographic study. The air sac system provides excellent contrast with soft tissues. Their small size reduces exposure required to produce an image. Positioning is easily accomplished if proper equipment is available. Avian anatomy is relatively simple, allowing easy interpretation. Radiology should be used to identify problems in birds with vague clinical signs. Respiratory tract disease is common and radiographs are useful in determining the extent of involvement. Radiographs are indicated in any bird with clinical signs of weight loss (wasting), vomiting, regurgitation, polyuria/polydipsia, or abdominal swelling (although details may be obscured in these cases). Orthopedic conditions such as fractures, of course, are indications for radiographs. Also, routine health screens may include radiographs, since much valuable information can be obtained.

Ventrodorsal and lateral whole body views should be taken (Figure 1). A restraining device and/or general anesthesia will facilitate obtaining diagnostic films. An acrylic plate with restraint mechanisms for the head and legs will facilitate positioning. The wings are restrained with masking tape or other means. Technique will vary with each machine and an avian technique chart will eliminate many retakes. Rare earth or non-screen film should be used to improve detail. Recent increases in availability of digital radiography have offered another increase in the detail that can be achieved.[1] The focal film distance will sometimes be reduced to give some magnification and to increase radiographic density without increasing kVP. Fast exposure times (1/60 sec or faster) are necessary to avoid excessive motion on the films. Care should be taken to minimize stress during these procedures. The patient must be examined to determine if it will tolerate the restraint necessary for good films. The procedure may have to be postponed until the patient is stabilized in some cases. Anesthesia (isoflurane) may be safer in a bird that struggles excessively. The technique should be set and all supplies ready before the bird is restrained.

Figure 1

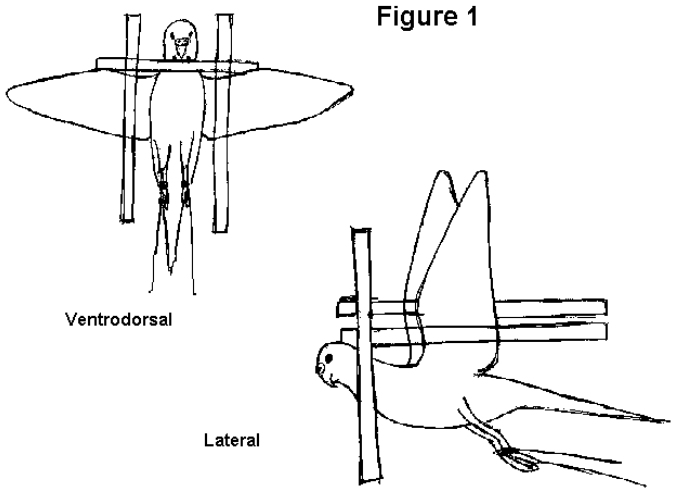

Contrast studies may be indicated in cases of gastrointestinal, urinary tract, or rarely respiratory disorders. The GI barium series is the most commonly performed contrast procedure. The barium

is administered by crop tube and radiographs taken immediately, at 15-30 minutes, at 60 minutes, and at 4 hours. The amounts of barium to be given are given in Table 1.

TABLE 1	
Budgie:	1cc
Cockatiel:	3cc
Amazon:	10-20cc
Macaw:	30cc

Normal transit of barium through the GI tract is rapid (Table 2).

TABLE 2	
Immediate:	barium in crop and proventriculus
15-30 min:	crop, proventriculus, ventriculus, 1/2 of intestines.
60 min:	whole gastrointestinal tract.
4 hours:	crop empty and barium in feces.

Excretory urograms, contrast sinograms, or cloacagrams are occasionally indicated. Intravenous contrast media are given (Renographin 75, 2 cc/kg) and films are taken immediately and in 5 minutes. The kidneys, ureter and, to some degree, the cloaca will be outlined.

As in any other species, normal anatomy must be learned before radiographic interpretations can be made. Radiographs should be examined systematically.[2] The radiograph should be evaluated for technique and positioning (not to pass judgment but to avoid misinterpretation of artifacts). The radiograph is then examined starting with the skin and working inward to the deepest tissues. Then each system is followed from cranial to caudal. Figure 2 shows the general

avrad

radiographic anatomy of a normal cockatiel.

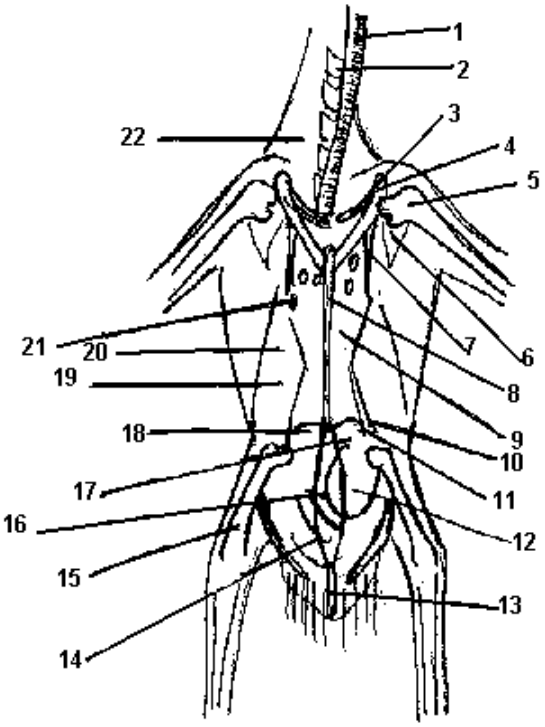

Ventrodorsal View

1 Trachea
2 Cervical vertebrae
3 Clavicle
4 Coracoid
5 Humerus
6 Clavicular air sac
7 Scapula
8 Sternal carina
9 Heart
10 Lateral border of liver
11 Proventriculus
12 Ventriculus
13 Pygostyle
14 Intestines
15 Femur
16 Synsacrum
17 Area of spleen
18 Cranial division of kidney
19 Caudal thoracic air sac
20 Lung
21 Great vessel
22 Crop

Lateral View

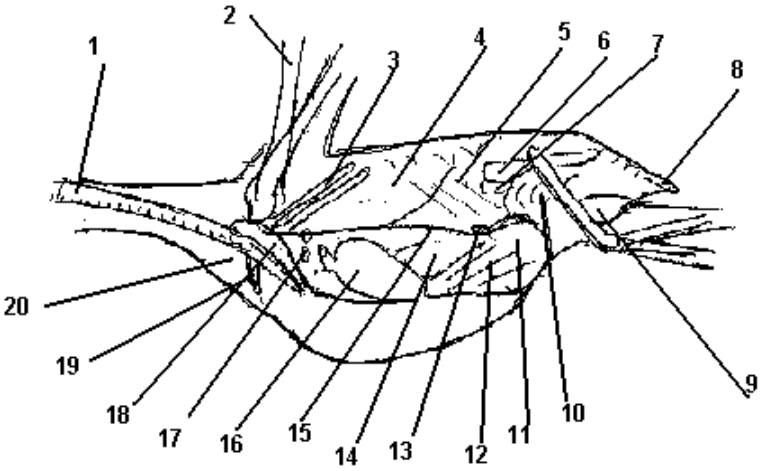

1 Trachea
2 Humerus
3 Scapula
4 Lungs
5 Vertebral ribs
6 Cranial division of kidney
7 Gonad
8 Pygostyle
9 Cloaca
10 Intestines
11 Ventriculus
12 Sternal ribs
13 Spleen
14 Liver
15 Proventriculus
16 Heart
17 Great vessels
18 Coracoid
19 Clavicle
20 Crop

Skeletal: head, neck, spine, synsacrum, pygostyle, appendages

Respiratory: nasal and paranasal cavities, pharynx, trachea, syrinx, lungs, air sacs

Gastrointestinal: mouth, cervical esophagus, crop, thoracic esophagus, proventriculus, ventriculus, intestines, cloaca

Urinary: kidney, cloaca

Genital: gonad, oviduct, cloaca

Cardiovascular: heart, great vessels

Liver

Spleen

Radiographic lesions include changes in size, position, or opacity of organs.

Skeletal System[3,4,5,6]
The skeletal system of birds has considerable fusion and reduction of bones in both the axial and appendicular skeleton. This is a weight-reducing measure, an adaptation for flight. Thin cortices and air sac extensions into certain bones (e.g. the humerus) in place of marrow further reduce their weight. The most common radiographic lesions of the skeletal system are **fractures**. Fractures should be described in the same manner as in mammals with regard to position, type, and evidence of skin wounds in the area. Sharp edges of a fracture suggest an acute problem while smoothing of the edges suggest chronicity. Healing of fractures is similar to mammals except that the endosteal and cortical callus are more important than periosteal callus. Avian bones tend to heal rapidly. **Metabolic bone disease** is not common despite the poor diets often given to birds. When it is seen, it is usually in baby birds. Either the parent birds are not eating an adequate diet or the owner is handfeeding an inadequate diet. African Grey parrots and cockatoos seem more prone to this disease than other psittacine birds. Adult birds are relatively resistant to bony changes caused by inappropriate Ca:P ratios, or vitamin D deficiency. Radiographically, the bones will be reduced in opacity, have abnormal curvature, may have increased matrix production, and may have pathologic fractures. Changes are seen in both the axial and appendicular skeleton. Occasionally, adult birds will have well mineralized, but curved or otherwise deformed bones. This is suggestive of earlier metabolic bone disease. The distinction between **osteomyelitis** and **neoplasia** is somewhat easier in birds than in mammals. The response to infection is generally new bone production. The response to neoplasia is generally osteolysis. The area of osteolysis may show sharp delineation, even during an active process. Increased mineralization of the long bones often occurs in birds with **estrogen stimulation** (i.e. prior to egg laying, or with gonadal hypersecretion). This radiographic finding has not been reported in association with severe cardiopulmonary disease (hypertrophic osteodystrophy) in birds as it has in mammals.

Respiratory System[7]
The respiratory tract of birds is very often evaluated radiographically. Respiratory disease is common and radiography can often help pinpoint a lesion or determine the extent of involvement. The **paranasal sinuses** can be evaluated on quality skull films. The process of obtaining quality skull films is somewhat time consuming and often is reserved for more chronic

cases which have not resolved with treatment based on more easily obtainable information. Anesthesia is required and positioning must be perfect for evaluation of the sinuses. Any increase in opacity, usually detected by comparison to the opposite side, is an indication of disease. The **trachea** is easily identified radiographically. Several radiographic signs may be seen in the trachea. Increased opacity of the tracheal rings may be seen as an aging change. An increase in the luminal diameter usually occurs with severe dyspnea. These birds should be handled with care to avoid excessive stress. A decrease in the diameter of the trachea is rare but usually indicates tracheal trauma. Foreign objects of sufficient size may be seen as focal opacities within the lumen of the trachea. Millet seeds in cockatiels are the most common tracheal foreign bodies. Displacement of the trachea may occur with extraluminal masses. Because of its location among many other structures, the **syrinx** may be difficult to visualize radiographically. Occasionally an increase in opacity can be discerned. This usually occurs with fungal granulomas or foreign objects. The syrinx is a common site for these lesions since the airways narrow abruptly at this point. The **lungs** of normal birds can be seen best in the lateral radiograph as a fine reticular pattern in the craniodorsal ceolom. The reticular pattern represents the parabronchi, which are present in place of alveoli of mammals. Generalized increases in the opacity of the lungs can be an indication of pulmonary edema or diffuse pneumonia (usually bacterial). Focal opacities within the lungs indicate granulomatous pneumonia (usually fungal) or neoplasia (rare). End-on blood vessels seen cranial and dorsal to the heart should not be mistaken for masses. The **air sacs** should be seen as gas densities. The membranes are generally too thin for radiographic visualization. Overinflation of the air sacs, giving a barrel shaped body cavity is usually an indication of upper airway stenosis; often a fungal granuloma at the syrinx is involved giving a ball valve-like effect. Decreased filling of the air sacs usually indicate abdominal enlargement compressing the air sacs. A generalized increase in the opacity of the air sacs can be seen with obesity, air sacculitis (usually bacterial) or hemorrhage. Focal opacities are usually granulomas (most often seen with aspergillosis). Mineralization of the air sac walls usually indicates visceral gout, while thickening of the air sac membranes indicates chronic (usually fungal) air sacculitis.

Digestive Tract

The mouth, esophagus, and crop can often be better evaluated by palpation, direct visualization, and endoscopy than radiographically. Distention of the **crop** is a common radiographic lesion and can be seen with luminal (tumors, granulomas, foreign bodies) or extraluminal obstruction (thyroid enlargement) distal to the crop, inflammation of the crop itself, or anything that causes a generalized ileus. Proventricular dilatation syndrome affects the crop in a substantial percentage of cases. Crop burns, fistulas, or lacerations may lead to accumulation of food and cellulitis in the subcutaneous tissue surrounding the crop appearing similar to distention of the crop. Barium studies of the crop may aid in distinguishing between these. Barium however is irritating to tissues, which may complicate the matter. If perforation is suspected, IV contrast agents may be substituted for barium. The **proventriculus** varies with species, age, and feeding, but is normally spindle shaped in adult, fasted psittacine birds. On ventrodorsal views the left border is roughly even with the left lateral border of the liver (if the liver is of normal size). Gas is never present in normal birds with the exception of dyspnic or extremely fractious individuals in which aerophagia may occur. The presence of gas, enlargement, or changes in shape or position are common radiographic signs.[8,9] Barium administration is recommended to better delineate the proventriculus and to detect masses, foreign bodies, or other luminal defects. Diseases causing proventricular lesions are proventricular dilatation syndrome, neoplasia, papillomatous disease, foreign body[10] ingestion, megabacteriosis, candidiasis, trichomoniasis and other gastrointestinal granulomatous diseases. Generalized ileus caused by sepsis or heavy metal toxicosis can lead to

proventricular dilatation. It should be noted that the proventriculus of neonates would appear much larger than birds that are weaned. The **gizzard or ventriculus** is often filled with mineral dense gravel and so often serves as a landmark for identification of other viscera. On lateral views, it sits on the ventral body wall just at the caudal end of the sternum. On ventrodorsal views, it sits to the left of the midline just caudal to the acetabula. The ventriculus is very muscular and gross dilation is unusual despite the fact that proventricular dilatation syndrome does affect this organ as well. This organ is the most common site for small foreign objects to localize since exit from the ventriculus is particle size dependent. Metallic foreign objects are often seen radiographically. Lead or other heavy metal toxicoses should be considered (but not confirmed) when metallic densities are seen. The absence of metallic foreign objects, however, does not rule out lead poisoning either as some sources of lead are difficult to visualize radiographically. The **intestines** occupy the ventral caudal abdomen. No simple rules exist for evaluating the size of intestinal loops. Dilated loops of bowel can be seen with mechanical (obstructive) ileus or, more commonly, with functional ileus. Functional ileus occurs with sepsis, heavy metal toxicosis, egg related peritonitis, and many other severe, debilitating diseases. Neonates normally have bowel loops that appear dilated when compared to an adult of equivalent size. The **cloaca** can be seen radiographically if full or may not be visible if empty. Radiographic identification of cloacal lesions that cannot be seen during direct examination is rare. Cloacaliths, usually urate concretions, can be seen with dehydration, cloacal dysfunction (e.g. neurologic damage), or severe cloacitis.

Urinary Tract[11]

The urinary tract of birds includes the kidneys, ureters and the cloaca. Birds have no urinary bladder. Radiographically, the **kidneys** occupy the dorsal body cavity caudal to the acetabula. The kidneys lie in pockets of bone on the ventral surface of the synsacrum. The cranial division bulges out ventrally and can be seen most easily on the lateral radiograph. The cranial border can sometimes be seen on VD films as well. Nephromegaly must be distinguished from silhouetting of the kidneys with the gonads, which sit cranial and ventral to the kidneys. Oblique views may be required to distinguish the right from the left kidney. Generalized nephromegaly is seen with gram negative, chlamydial and other infections of the kidney, as well as with some toxicoses (esp. lead). The lack of a bladder and the presence of a renal portal system make the avian kidney more susceptible to infection than their mammalian counterparts. With focal enlargements, especially in budgerigars, renal tumors should be suspected. Increased opacity of the kidneys can occur with metabolic (e.g. hypervitaminosis D) or dystrophic (e.g. renal necrosis) calcification or with renal constipation, a condition associated with dehydration. The **ureters** are not generally visible radiographically but if abnormalities are suspected an excretory urogram can be performed.

The **male and female gonad** can be visualized on lateral radiographs if they are active. They are cranioventral to the kidneys. Ovarian follicles are very large just prior to ovulation and this should not be misinterpreted as pathology. Ovarian and testicular neoplasias do occur and will show enlargement of the respective gonad. Ascites is often present as well. The active **oviduct** occupies a large portion of the dorsal body cavity and is very convoluted making radiographic visualization difficult in reproductively active hens. Fully shelled or unshelled eggs may be seen in the oviduct or free in the body cavity. It may be difficult to determine if the egg is free within the abdomen or in the oviduct based on radiographs. Often, there is simply a generalized lack of detail and other techniques (i.e. ultrasound) are needed to distinguish fluid from eggs, masses or organs. A cranial or ventral displacement of the ventriculus may be seen with enlargements in the reproductive tract or kidney.

Cardiovascular System

The **heart** is difficult to evaluate radiographically in birds since the size changes dramatically with the cardiac cycle. A determination of cardiomegaly should be based on increased basilar to apical dimension, prominence of the left atrium, abnormal shape, or enlarged vascular structures. Cardiomegaly is usually caused by cardiomyopathy, most often dilated but hypertrophic has been reported. Cardiomyopathy in psittacines is usually idiopathic but may occasionally be associated with vitamin E deficiency. In mynahs, toucans, and certain other softbills, it can be seen with hemochromatosis. The **great vessels** are visible cranial and dorsal to the heart. An increase in the size of these vessels may be seen in birds with congestive heart failure. Mineralization of the great vessels will occasionally be seen, especially in aged patients. This finding may also be associated with hypervitaminosis D or hypercalcemia.

Liver

The liver is most easily seen on VD radiographs. It begins narrow at the heart's apex, forming an hourglass shadow with the heart as it widens caudally. The normal liver does not extend outside a line drawn from the scapula to the greater trochanter of the femur. On the lateral view, the liver should not extend caudal to the end of the sternum. Radiographic signs of hepatomegaly include widening of the liver shadow with loss of the hourglass shape, caudal and dorsal displacement of the ventriculus, or alteration of the shape of the liver. The liver lobes surround many other viscera and enlargement of these organs can lift up the lobes, thus widening the liver shadow, and giving the appearance of hepatomegaly. The position of the ventriculus should aid in distinguishing this from true hepatomegaly. Hepatomegaly can be caused by infectious agents (i.e. Pacheco's virus, chlamydiosis, mycobacteriosis, gram negative hepatitis, etc.), metabolic diseases (i.e. hepatic lipidosis, hemochromatosis), or toxicoses (i.e. lead poisoning). These generally cause diffuse hepatomegaly. Neoplasia can cause focal or generalized enlargements. Neoplasia of the liver is uncommon but lymphoma by itself or in association with avian leukosis virus (in passerines) and biliary adenocarcinoma associated with cloacal papillomas (in South American parrots, especially Amazons) are sometimes seen. A small liver indicates a chronic, fibrotic disorder.

Spleen

The spleen is normally seen at the junction of the proventriculus and ventriculus. The normal size limit is roughly 0.8 cm in a 400g Amazon or 0.2 cm in a 100 g cockatiel. Enlargement of the spleen is usually seen with chronic infectious processes. Splenomegaly is classic for chlamydiosis but is not always seen with this disease and is not pathognomonic for it. Splenic neoplasia is uncommon in companion birds but lymphoma may be seen on occasion.

Alternative Imaging Techniques

Ultrasound[12],[13],[14]

Unlike conventional radiography, ultrasound depends upon the transmission or reflection of high frequency sound waves to form an image. Soft tissues and fluids transmit sound waves readily while bone and air tend to block and obscure the sound waves. As such, avian patients are comparatively poor candidates for this diagnostic method. However, more and more study is being done on the use of ultrasound in avian patients.[15] The liver provides the primary window for viewing in pet birds. The liver and heart are the only organs that are readily examined in these normal birds. With experience, the ventriculus, intestines, pancreas, gonads, and kidneys can be imaged. Birds with coelomic effusions have improved capabilities of ultrasound as a diagnostic modality while making both radiography and endoscopy more difficult or

dangerous.[11] Eggs are readily identified whether or not they have a calcified shell. Masses can be distinguished from free fluid.
Because it provides real time moving images, ultrasound provides unparalleled data regarding cardiac function. While some functions such as M-mode are still not readily achieved, chamber size, wall thickness, and contractility can be subjectively evaluated. Color flow Doppler can demonstrate valvular insufficiency or stenosis. Unlike radiography, ultrasound can easily distinguish between cardiac enlargement and pericardial effusion.

Ultrasound takes considerable practice to master. Unlike a radiograph, a scan takes a few minutes to half an hour. The time decreases as the experience of the operator increases. Consideration should be given to the stress involved with restraining a bird for the duration of the procedure, particularly in patients suspected of having heart disease.

Computed Tomography [6,16,17] and Magnetic Resonance Imaging[18]
While not commonly used in avian patients, computed tomography (CT) and magnetic resonance imaging (MRI) have been investigated as diagnostic techniques. Particularly in the skull, more diagnostic determinations can be made compared with plain radiography. Lack of availability of both equipment and personnel qualified to interpret these limit its application currently. The primary disadvantage, aside from cost, is the time under general anesthesia with only distant monitoring through a viewing window. However, very detailed images can be obtained and when needed, patients can be referred to universities or private specialty hospitals for these procedures. In particular, areas where numerous layers make radiographic interpretation difficult are clarified using these techniques. CT is excellent for the skull where the air in the sinuses contrast well with bone. Contrast material can be injected to improve visualization of soft tissue structures. MRI can distinguish soft tissues better than CT.

Nuclear Scintigraphy[19]
Nuclear scintigraphy employs the injection of a radiopharmaceutical agent and then imaging using a gamma camera. Depending on the agent used, it will accumulate in certain tissues or organs. Bone scans and renal scans are some of the more common applications. The accumulation may be accentuated or diminished by various disease states. This is a procedure that is only available in referral institutions and is not yet well researched in avian species.

---

[1] Nemetz LP, Principles of high-definition digital radiology for the avian patient. Proc Annu Conf AAV 2006 pp 39-45.
[2] Silverman S. Advanced avian radiographic interpretation. Proc Annu Conf AAV 1989.
[3] Kostka V et al. A contribution to radiologic examination of bone alterations in psittacines, birds of prey, and pigeons. Proc Annu Conf AAV 1988.
[4] Kirchner S. Radiological monitoring of the ossification of the skeleton of young racing pigeons. Proc Annu Conf AAV 1992.
[5] Scheideler SE et al. Determination of baseline values for skeletal (leg bone) growth, calcification, and soft tissue (liver) mineral accretion. Proc Annu Conf AAV 1994.
[6] Kostka V, Krautwald ME, Tellhelm B. Radiology of the avian skull: techniques, radiographic anatomy, and pathology. Proc Annu Conf AAV 1989.
[7] Krautwald-Junghanns ME. Radiology of the respiratory tract and the use of computed tomography in psittacines.
[8] Degrenes LA, Love NE, Laughery MC. Review of changes associated with proventricular dilation disease. Proc Annu Conf AAV 1996.
[9] Bond MW, Downs D, Wolfe S. Screening for psittacine proventricular dilatation syndrome. Proc Annu Conf AAV 1993.
[10] Ingram IA. Proventricular foreign body mimicking proventricular dilatation in an umbrella cockatoo. Proc Annu Conf AAV 1990.
[11] McMillan MC. Imaging of urogenital disorders. AAV Today 2:2. 1988:74-83

[12] Rosenthal K et al. Ultrasonic findings in 30 cases of avian coelomic disease. Proc Annu Conf AAV 1995.
[13] Blue-McLendon A Homco LS. Ultrasound determination of yolk sac size in ostrich chicks. Proc Annu Conf AAV 1995.
[14] Phalen D. Investigations into the etiologic agent of internal papillomatosis of parrots and ultrasonographic and serum chemical changes in Amazon parrots with bile duct carcinomas. Proc Annu Conf AAV 1997.
[15] Krautwald–Junghanns ME, Pees M. Non-invasive imaging diagnostic techniques with special reference to the unofficial tract. Proc Annu Conf AAV 2006, pp 171-177.
[16] Rosenthal K et al. Computerized tomography in 10 cases of avian intracranial disease. Proc Annu Conf AAV 1995. Proc Annu Conf AAV 1995.
[17] Jenkins JR. Use of computed tomography (CT) in pet bird practice. Proc Annu Conf AAV1991.
[18] Romagnano A et al. Magnetic resonance imaging of the avian brain and abdominal cavity. Proc Annu Conf AAV 1995.
[19] Marshall KL et al. Avian renal scintigraphy. Proc Annu Conf AAV 2002 pp 165-166.